

MYCOTOXIN LESIONS IN THE SLAUGHTER HOUSE-BROILERS



SPECIAL NUTRIENTS, INC.
THE MYCOTOXINS SPECIALIST
www.mycotoxin.com

INTRODUCTION

Traditionally, the presence of mycotoxins capable of causing damage in animal production has been demonstrated by detecting certain levels in ingredients and / or rations. Since this technique has many limitations, histopathology has been used in many areas to demonstrate that these toxic agents are actually affecting the birds. Here we propose a practical approach to demonstrate their presence in commercial farms. By following this procedure, poultry companies will be able to determine if the mycotoxins identified in the feed are causing damage and if the preventive measures taken (anti mycotoxin feed-additives, mold inhibitors, silo management, etc.) are effective. The following table includes some of the organs that should

be evaluated weekly or monthly. It is important to emphasize that even the most efficient mycotoxins binders available in the market will not adsorb one hundred percent of the mycotoxins present in the feed, hence, the detection of some degree of lesions is expected when mycotoxins are present. At least 200 to 300 carcasses should be examined and periodically some tissue samples must be evaluated with histopathology. If possible, the inclusion of the evaluation of the Bursa of Fabricius in the table presented below, will offer important information on the status of the immune system. Besides the organs listed below, the flocks performance must be taken into consideration when evaluating the presence of mycotoxins.

EVALUATION		
ORGAN	LESION	CAUSE
Oral cavity	Ulcers, plaques	T2 / MAS / DAS
Gizzard	Erosion, ulcer	
Proventriculus	Enlargement	Cyclopiazonic acid
Liver	Pale, fatty, friable	Aflatoxin
Gall bladder	Pale content (bilis)	
Breast / wing / thigh	Bruises / hemorrhages	
Kidney	Inflammation, urate deposits	Ochratoxin

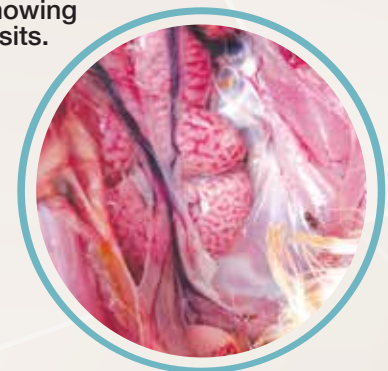URATE DEPOSITS AND SWOLLEN KIDNEYS

When urates are present, they look like grains of sand or small stones located inside the organ.

CAUSES

- ▶ Lack of drinking water.
- ▶ Excessive levels of calcium carbonate in feed.
- ▶ **Nephropathogenic strains of Infectious Bronchitis.**
Gray, Holte and Florida 88. Lately, new Chinese strains as QX and Q1 have been identified in China, Europe and Latin America.
- ▶ Ochratoxin.

Kidneys showing urate deposits.



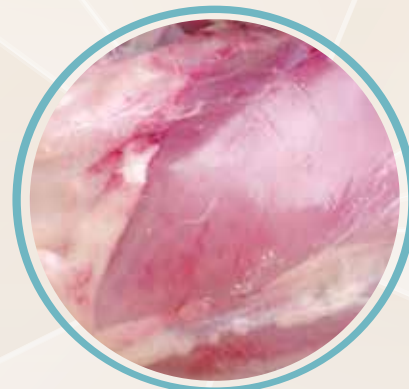BRUISES

Consist on the presence of a minor injury in muscles and / or subcutaneous tissue as a result of the rupture of small vessels (capillaries). The bruise color can indicate if they are recent (deep red, blue or black) or older (greenish or yellowish).

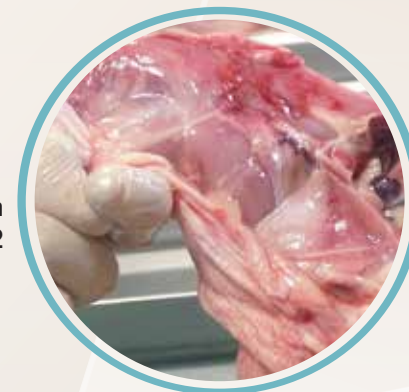CAUSES

- ▶ Aflatoxin.
- ▶ Gumboro's disease.
- ▶ Infectious chicken anemia virus.
- ▶ Improper stunning or bleeding during sacrifice.
- ▶ High density (birds / m² in chicken houses).
- ▶ Incorrect harvesting of broilers before transportation to slaughter houses.
- ▶ Intoxication with sulfa drugs.
- ▶ Vitamin K deficiency.

Recent bruises in the breast of a 34 day-old broiler.

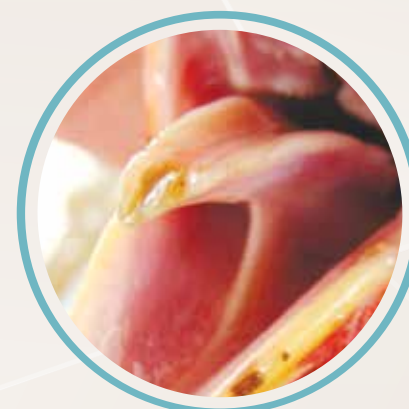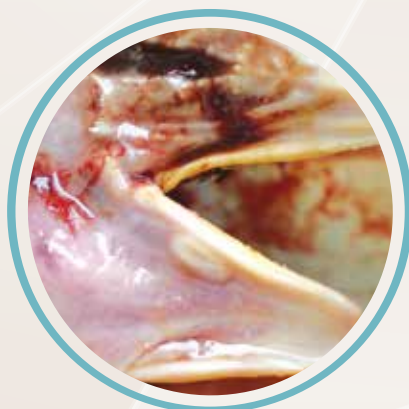

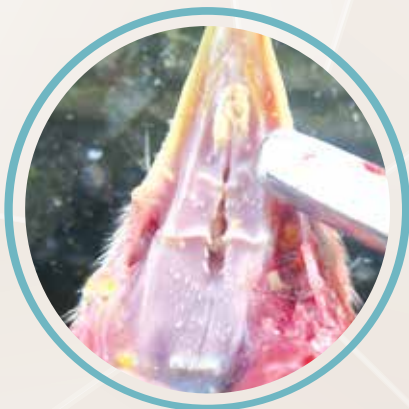
Recent bruises in the thigh of a 32 day-old broiler.



ORAL LESIONS

Present in the mouth and identified as mild to severe yellowish or whitish plaques and ulcers located in the palate, tongue, floor of the mouth, salivary ducts openings, and the interior margins of the beak. The healing process will only leave a minor scar tissue remaining in the area affected. In severe cases, necropsy of the tip of the tongue or the whole organ can be present. This lesion is mainly cause by T-2 toxin, DAS, MAS; member of the trichothecenes group of fusarium toxins. HT 2 toxin, a metabolite of T-2 toxin, could be also responsible for this lesion.

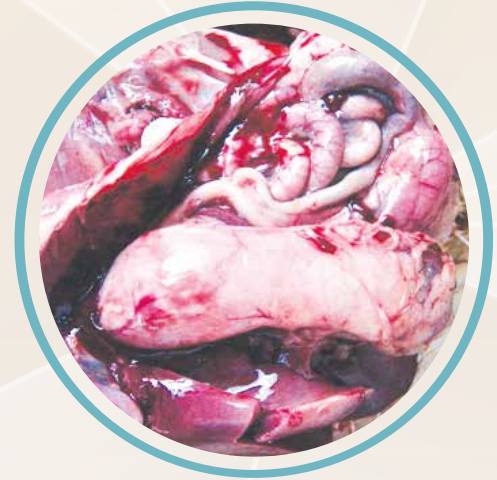

PROVENTRICULITIS / PROVENTRICULOSIS

Consist on the inflammation or enlargement of the proventriculus. It is associated with higher incidence of Salmonellosis and other zoonosis.

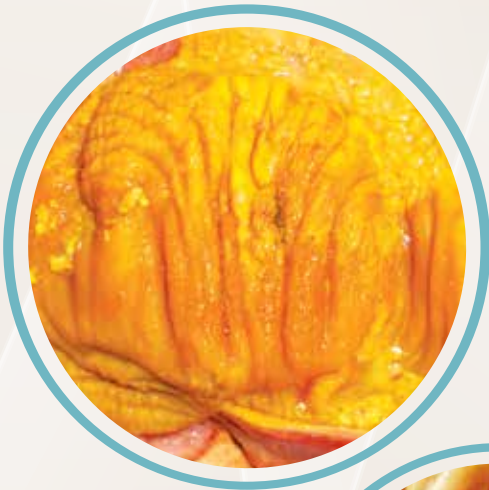CAUSES

- ▶ Infectious proventriculitis virus associated with Gumboro's disease.
- ▶ Marek's disease virus.
- ▶ Reovirus.
- ▶ Biogenic amines (blood, feather, meat and bone meals).
- ▶ CPA (Cyclopiazonic acid), a mycotoxin.



GIZZARD EROSION

Characterized by superficial to deep damage to the koilin layer of the gizzard.



CAUSES

- ▶ Mycotoxins (Tricothecenes).
- ▶ Biogenic amines (bone, blood, feather and meat meals).
- ▶ Prolonged stay of baby chicks in the hatcher after hatch.
- ▶ Fish meal.
- ▶ Copper sulfate.
- ▶ Adenovirus.
- ▶ Fasting in chicks.

MYCOTOXINS CAUSING EROSION

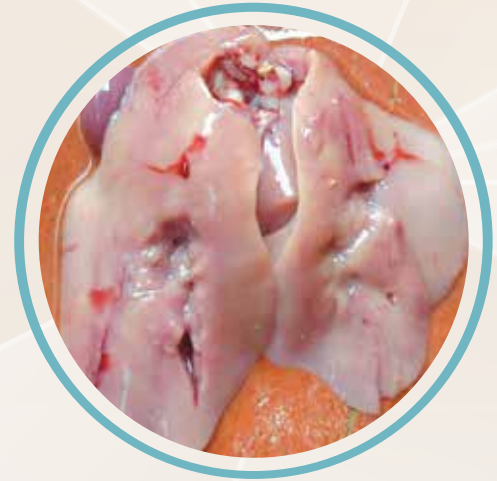- ▶ T-2 toxin.
- ▶ MAS (monoacetoxiscirpenol).
- ▶ DAS (diacetoxiscirpenol).
- ▶ HT 2 (metabolite of T-2 toxin).

PALE, YELLOW AND / OR FATTY LIVERS

Usually, the liver of healthy young birds (broilers and pullets) has a brown color with a compact appearance. When mycotoxins are present, the livers appear yellow and / or pale.

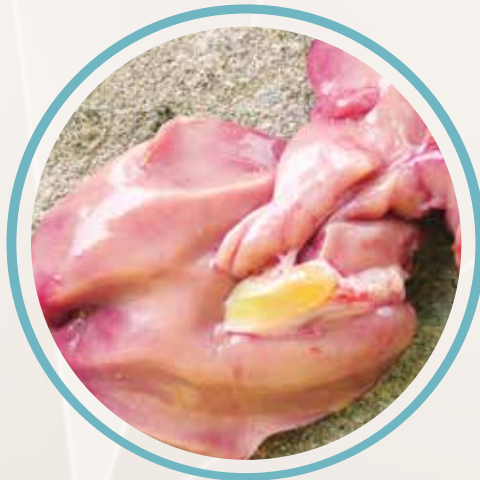CAUSES

- ▶ Aflatoxin.
- ▶ Fasting before slaughtering:
 - ✓ Full-fed broilers show lighter liver colors because of higher lipid concentration.
 - ✓ Broilers fasted for 12 hours show darker livers because of lower levels of fat.
- ▶ Fatty liver and kidney syndrome, associated with biotin deficiency.
- ▶ Choline deficiency.
- ▶ Poor quality oil / fat in broiler diets.

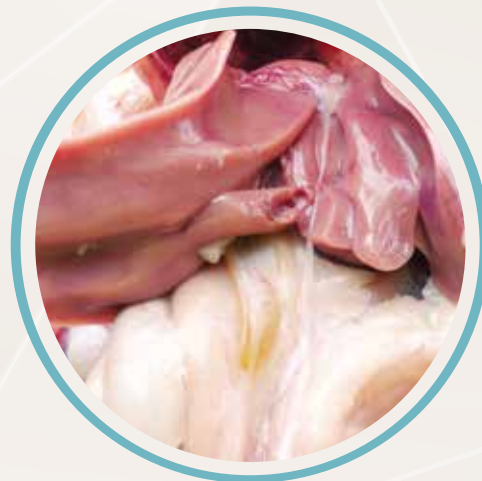

PALE GALL BLADDER CONTENT

Generally, aflatoxicosis can cause this type of lesion as a consequence of the damage produced in the liver that impairs its capacity of producing biliary salts with the proper concentration.



Bile with a pale appearance detected in 28 and 32 day-old commercial broilers.



Does your anti-mycotoxin additive meet the basic TOP and FACTS?

Copyright June 2016. Special Nutrients, Inc. All Rights Reserved.

Target  Organ Protection			
Mycotoxin	Organ	MYCOAD	MYCOAD AZ
Aflatoxin	Liver	YES	NO
Ochratoxin	Kidney	YES	NO
T-2 Toxin	Oral lesion	YES	YES
Fumonisin	Heart / Lung / Liver	YES	YES*
Zearalenone	Reproductive	N/A	YES
DON	Liver	N/A	YES
Facts		MYCOAD	MYCOAD AZ
<i>In vivo</i> dosage with TOP results		2.5 kg / MT	1 kg / MT
Recommended commercial dosage		2.5 kg / MT	1 kg / MT
The clay is always obtained from the same mine		YES	YES
Approved in Texas, USA, against Aflatoxin		YES	N/A
Approved in the European Union against Aflatoxin. Regulation #1831 / 2003 (1m 588)		YES	N/A
ENDOTOXIN adsorption		N/A	YES
Efficacy approved by LAMIC and other institutions against the following number of mycotoxins		4	4
Efficacy approved by LAMIC and other institutions in different types of animals		6	5
Nutrient absorption		NO	NO
<i>In vitro</i> efficacy test every:		100 MT	18 MT

* Test performed with 4 Kg / MT with 30,000 ppb of fumonisin
N/A= not applicable

Mycoad = Cobind, Toxfree Standard
Mycoad AZ = Cobind AZ, Toxfree



SPECIAL NUTRIENTS, INC.
THE MYCOTOXINS SPECIALIST
www.mycotoxin.com